

Suturable Mesh Demonstrates Improved Outcomes over Standard Suture in a Porcine Laparotomy Closure Model

Gregory A. Dumanian, MD

Background: Laparotomy closures fail due to suture pull-through. I hypothesize that a suturable mesh may limit pull-through via mechanisms of force distribution and fibrous encapsulation of the device filaments.

Methods: Fifteen domestic swine 74 kg in size were randomly allocated to three groups for laparotomy closure with either size 0 suturable mesh, number 1 suturable mesh, or number 1 polypropylene. All three devices were placed in running fashion with 1-cm bites and 1-cm travels. Primary endpoints were hernia formation at 13 weeks and a semiquantitative analysis of the histological tissue response. Secondary endpoints included adhesions, surgical site occurrence (SSO), and documentation of “loose sutures.”

Results: There were numerically fewer hernias in the number 1 suturable mesh group. Nine of the 10 suturable mesh devices were well encapsulated within the tissues and could not be pulled away, whereas four of the five polypropylene sutures were loose. Adhesions were least for number 1 suturable mesh. Histologically, the suturable mesh implanted devices showed good fibrovascular ingrowth and were judged to be “nonirritants.” The soft-tissue response was statistically greater ($P=0.006$) for the number 1 suturable mesh than for the number 1 polypropylene.

Conclusions: The mechanism by which meshes support closure sites is clearly demonstrated with this model. Suturable mesh has the potential to change surgical algorithms for abdominal wall closure. (*Plast Reconstr Surg Glob Open* 2021;9:e3879; doi: 10.1097/GOX.0000000000003879; Published online 15 October 2021.)

INTRODUCTION

Ventral hernia after routine laparotomy is the most common major complication in general surgery with a 10%–23% occurrence rate. Incisional hernia formation and optimal closing of the laparotomy incision is the focus of much discussion and research.^{1,2} One cause of these failures is “suture pull-through.” Like a wire cutting through ice or cheese, the sharp suture filament either acutely or chronically cuts through abdominal wall tissues, leading to

dehiscence in the acute situation and incisional hernia formation when the wound healing failure occurs over time.

A suturable mesh was developed to limit pull-through while approximating tissues. Suturable mesh is made of individual polypropylene filaments that are latticed together in a hollow cylindrical configuration with a macroporous outer mesh wall. Meshes are well established in their ability to maintain tissues in apposition after repair with improved outcomes over standard sutures.^{3,4} A suturable mesh prototype was tested in a rat hernia model. Eighty-five percent of the standard sutures pulled through the abdominal wall, but every suturable mesh prototype maintained its hold on the abdominal wall.⁵ A realistic porcine laparotomy model demonstrated a stronger earlier

From the Stuteville Professor of Surgery and Chief of Plastic Surgery, Northwestern Feinberg School of Medicine, Chicago, Ill. This study was funded entirely by MSi.

Received for publication July 15, 2021; accepted August 27, 2021.

Presented at the Americas Hernia Society Meeting in Austin, TX, in September 2021. Presented at the European Hernia Society Joint Congress in Copenhagen, Denmark, in October 2021.

Copyright © 2021 The Author. Published by Wolters Kluwer Health, Inc. on behalf of The American Society of Plastic Surgeons. This is an open-access article distributed under the terms of the Creative Commons Attribution-Non Commercial-No Derivatives License 4.0 (CCBY-NC-ND), where it is permissible to download and share the work provided it is properly cited. The work cannot be changed in any way or used commercially without permission from the journal.

DOI: 10.1097/GOX.0000000000003879

Disclosure: Dr. Dumanian is the inventor of suturable mesh, and medical officer of MSi. He has intellectual property and ownership interest in MSi. The primary investigator for the study, the veterinarians, the necropsy surgeon, the pathologists, and the quality auditors for each site were all contracted by MSi but had no other financial interest in the study.

Related Digital Media are available in the full-text version of the article on www.PRSGlobalOpen.com.

repair at 8 days with a suturable mesh prototype than with standard suture.⁶ Cadaveric abdominal wall studies with suturable mesh showed that even without fibrovascular incorporation, the suturable mesh showed increased resistance to pull-through in comparison to monofilament suture in an abdominal wall model.⁷

A knowledge gap existed as to the efficacy of a suturable mesh to maintain tissue approximation for longer than 8 days. We hypothesized that a suturable mesh used for laparotomy closure would demonstrate improved macroscopic and microscopic outcomes in comparison to standard suture. To this end, a preclinical study was conducted to compare the outcomes of 0 suturable mesh and number 1 suturable mesh with standard number 1 polypropylene monofilament suture. Primary endpoints were hernia formation at a 13-week sacrifice and histological tissue response. Secondary endpoints included adhesions, surgical site occurrence, documentation of “loose sutures” (ability to distract the suture away from the tissues), adverse events, and change in animal weight.

MATERIALS AND METHODS

Animals

All animal procedures and housing were performed under protocols approved by the University of Saskatchewan Animal Research Ethics Board. Fifteen nulliparous and non-pregnant female pigs (*Sus scrofa domestica*) weighing approximately 72 kg were used for the study (Prairie Swine Centre, Saskatoon, Canada). Fifteen animals were randomly divided among the three groups.

Implants

The suturable mesh (Duramesh Suturable Mesh, MSi) is manufactured from 12 polypropylene filaments for the

Takeaways

Question: Can a novel tissue approximation device improve on the tendency of sutures to tear through tissues, leading to surgical failure and hernia formation?

Findings: Suturable mesh elicits an inflammatory response comparable to that of a standard suture in its quality, yet is larger in size to provide additional support at the suture/tissue interface. This novel device acts as a scar scaffold. Fibrous incorporation of its fine filaments occurs without capsule formation, leading to fewer loose sutures and numerically fewer hernias as compared to a standard suture.

Meaning: Suturable mesh is a more reliable tissue approximation device than a standard suture.

0 size and 18 filaments for the number 1. The implant is 36 inches long and has an attached swaged standard surgical needle. The 0 suturable mesh has an inner diameter of 2 mm, and the number 1 has an inner diameter of 3.4 mm. The Duramesh device is investigational and not yet allowed for use in the United States. For a comparison suture, a number 1 polypropylene monofilament (Surgipro, Covidien, Minneapolis, Minn.) was chosen as it is an accepted suture for fascial closure (Fig. 1).

Surgical Procedure

A ventral midline abdominal skin incision 17 cm in length was made sharply from the xyphoid to the umbilicus. A 2.5-cm wide area of linea alba was cleared of soft tissue with cautery. The linea alba was opened, and the peritoneum incised. Three centimeters of peritoneum and preperitoneal fat were excised from both hemiabdomens

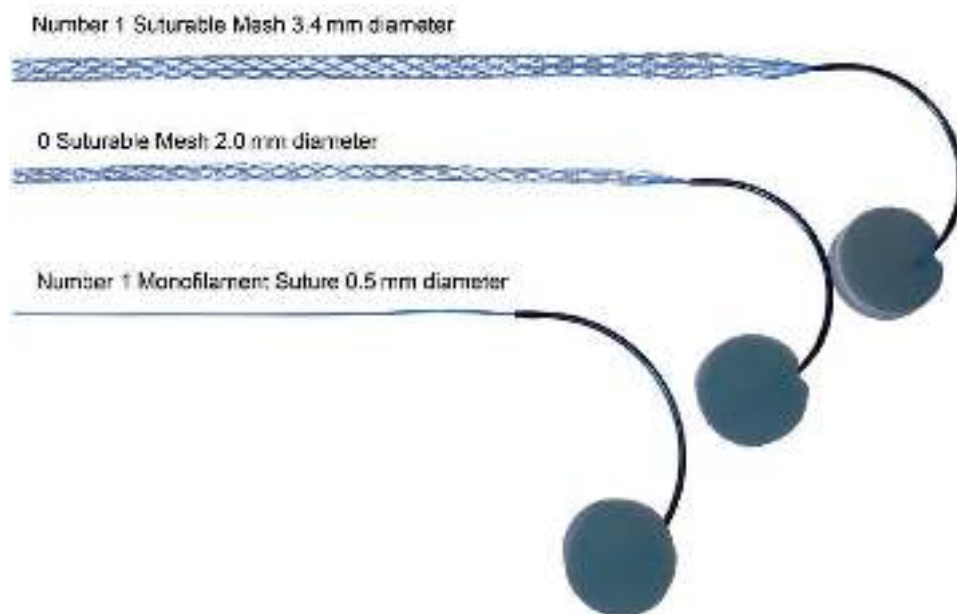


Fig. 1. Number 1 suturable mesh (top), 0 suturable mesh (middle), and number 1 polypropylene suture with attached needles used in protocol.

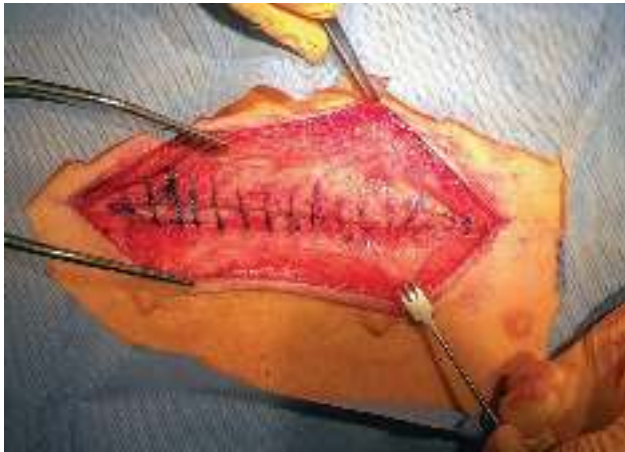

Fig. 2. Closure of 15 cm epigastric laparotomy incision with number 1 suturable mesh.

for the length of the laparotomy incision. One-centimeter hash marks were drawn with a surgical marking pen to ensure 1-cm bites and 1-cm travels. The linea alba was randomly closed with either suturable mesh or polypropylene monofilament in a simple continuous (running) suture pattern. A knot was created at each of the two opposing ends of the incision, and the sutures were run toward each other then tied to each other in a third knot (Fig. 2). A video of the implantation is available here: <https://youtu.be/glCxHgDg0Pk>. The subcutaneous tissues were closed using interrupted and running 2-0 polydioxanone sutures.

Animal Care

Each pig was weighed before surgery and then weekly, before necropsy. Incision observations were recorded

Table 1. Scoring System for Visceral Adhesions at Necropsy

Adhesion Scoring, Extent	
Score	Percent of material area involved with adhesions
0	No adhesions
1	1% to 25%
2	26% to 50%
3	51% to 75%
4	Greater than 75%
Adhesion Scoring, Severity	
Score	Percent of material area involved with adhesions
0	No resistance to separation
1	Mild resistance to separation
2	Some resistance (moderate force is required)
3	Sharp dissection needed
Adhesion Scoring, Degree/Intensity	
Grade	Description
0	No adhesions present
0.5	Thin, translucent adhesions composed of few fibrinous strands
1	Continuous fibrous, avascular adhesions; disrupted by gentle blunt dissection
2	Fibrous adhesions, some vascularity; disruption of adhesions requires sharp dissection; identifiable tissue planes
3	Dense scar with obliteration of tissue planes

Table 2. Scoring System for Abdominal Wall Integrity at Necropsy

Scoring System for Suture Pull-through/ Hernia Formation at Necropsy
No evidence suture pull-through, abdominal sutures intact
Abdominal suture loose
Abdominal suture with evidence of minor pull-through
Abdominal suture with evidence of consistent pull-through but still connected to both sides of the abdominal wall
Abdominal suture has pulled through one side of the abdominal wall
Minor defects in abdominal wall, no hernia
Small hernia < 1 cm present
Multiple small hernias present < 1 cm
One larger hernia 1–3 cm present
Multiple larger hernias 1–3 cm wide present
Large hernia 3–6 cm wide present
Massive hernia > 6 cm wide present

daily. Physical examination of the pigs was performed at 1 month, 2 months, and before necropsy.

Necropsy

At necropsy, the suture line for each animal was graded for adhesion formation between the peritoneal side of the suture line and adjacent abdominal organs using the scoring table (Table 1). The abdominal wall was then examined carefully for evidence of loose sutures, suture pull-through, and abdominal wall defects scored as per Table 2.

Pathology Evaluation and Analysis

The sutured incision sites were excised and the excised blocks of tissues were trimmed to allow a sufficient area around the implant for proper histological preparation. Three cross sections were obtained from each sutured incision site and identified as cranial, middle and caudal. A section was then obtained to the left of the incision line from the cranial end, a section to the right of the incision line from the middle portion, and a section to the left of the incision line from the caudal end, each at approximately 1–3 mm away from the incision line (Fig. 3). These sections were embedded in methyl methacrylate (MMA) and subsequently polymerized. Thin, approximately 8 µm, sections from each block were stained with hematoxylin and eosin (H&E). A semiquantitative descriptive microscopic evaluation of histology sections (sutured incision sites) was performed by a certified veterinary pathologist (AccellAB, Montreal, Canada). The sections were analyzed and graded according to cell type and tissue response. The quality of the tissue response to the implant was evaluated following the irritancy/reactivity grading scheme adapted from the ISO 10993-6 Annex E.⁸ Assessment of the size of the soft-tissue response surrounding the three implants using measurements taken using an optical micrometer (Fig. 4) was made to illustrate differences in histological response. A semiquantitative microscopic evaluation of tissue ingrowth was performed as per Melman.⁹ As the suturable mesh and the comparison standard suture have different appearances under the microscope, the pathologist could not be blinded as to implant type.

Statistical Analysis

No statistics were used to assess the primary endpoint of hernia formation. For histology, equal variance and

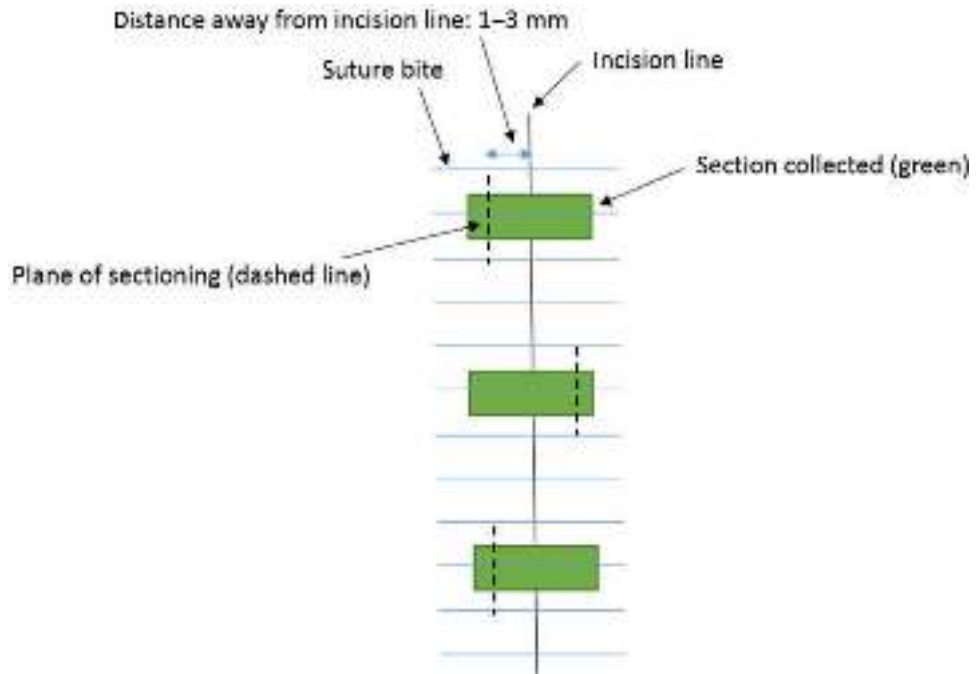
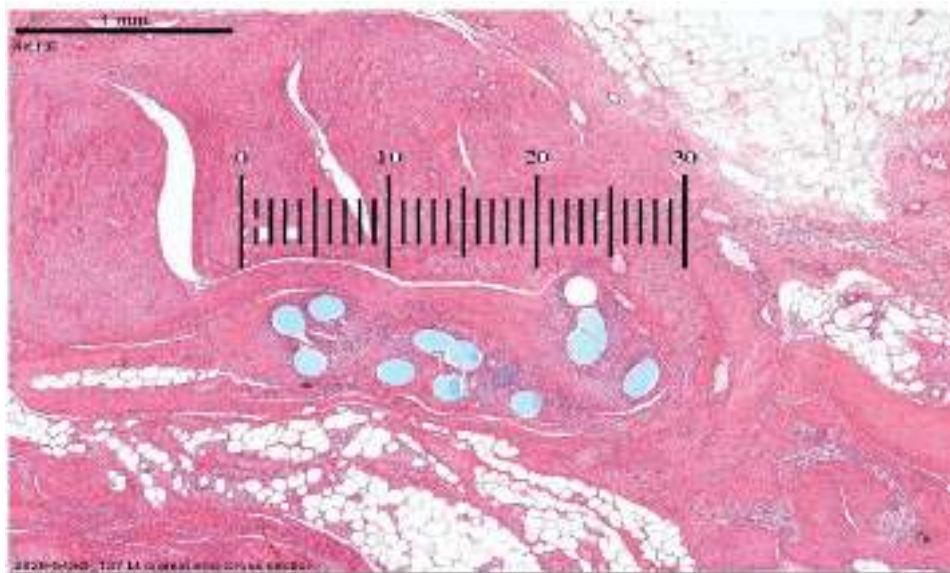


Fig. 3. Diagram of tissue blocks taken for histologic analysis of midline closures.



Grade	Diameter (micrometer units at 2x magnification)
0	<10 U
1	10-20
2	20-30
3	30-40
4	>40 U

Fig. 4. Grade of tissue response quantitated histologically.

normality tests were performed. When both were successful, one-way analysis of variance (ANOVA) means tables with Dunnett tests were used to calculate the significance of differences between continuous variables of the study implant groups. When either equal variance test or normality test failed, a Kruskal–Wallis one-way ANOVA on ranks with Dunn’s method was conducted. A *P* value of less than 0.05 was considered statistically significant.

RESULTS

Hernia Formation

For the primary endpoints, there were numerically fewer hernias with the number 1 suturable mesh than the 0 suturable mesh or the number 1 polypropylene sutures. All of the animals with intact abdominal walls were in the suturable mesh groups (Figs. 5 and 6). All of the polypropylene monofilament closures demonstrated small abdominal wall defects (Fig. 7).

Histology

Neovascularization was significantly higher for 0 suturable mesh and number 1 suturable mesh as compared to number 1 polypropylene ($P = 0.005$). The 0 suturable mesh had a score of 2.53 ± 0.51 for tissue ingrowth on a three-point scale. The number 1 suturable mesh had a score of 2.33 ± 0.63 for tissue ingrowth on the same scale. The polypropylene suture is solid standard suture and, therefore, did not permit any tissue ingrowth.

Both sizes of suturable mesh at 3 months were regarded as nonirritants to the tissues in comparison to polypropylene monofilament using the semiquantitative histological scoring system. Capsule formation was not noted in any of the samples, and therefore capsular thickness was not measured. The dimensions of the soft-tissue response were graded as 3.93 ± 0.15 for number 1 suturable mesh, 3.40 ± 0.15 for the 0 suturable mesh, and 2.13 ± 0.99 for number 1 polypropylene monofilament (Fig. 8). (See figure, Supplemental Digital Content 1, which displays histologic cross-section of number 1 polypropylene suture (top), 0 suturable mesh (middle) and number 1 suturable mesh (bottom) after staining with hematoxylin and eosin (left), and Masson’s trichrome (right). Implantation of all devices is associated with mild peridevice inflammatory response characterized by a presence of macrophages and multinucleated giant cells as well as lymphocytes, plasma cells, and polymorphonuclear cells. The number 1 polypropylene is characterized by a region of fibroplasia surrounding the suture monofilament and neovascularization. Suturable meshes are characterized by presence of fibroplasia (organizing fibrous connective tissue) and neovascularization surrounding, and occasionally intercalating between strands of the multifilament suture material (C–F), <http://links.lww.com/PRSGO/B811>.) There was a statistical difference between the groups ($P < 0.0001$).

Secondary Endpoints

The pigs gained weight equally during their 13-week observation and were approximately 150 kg at necropsy. All

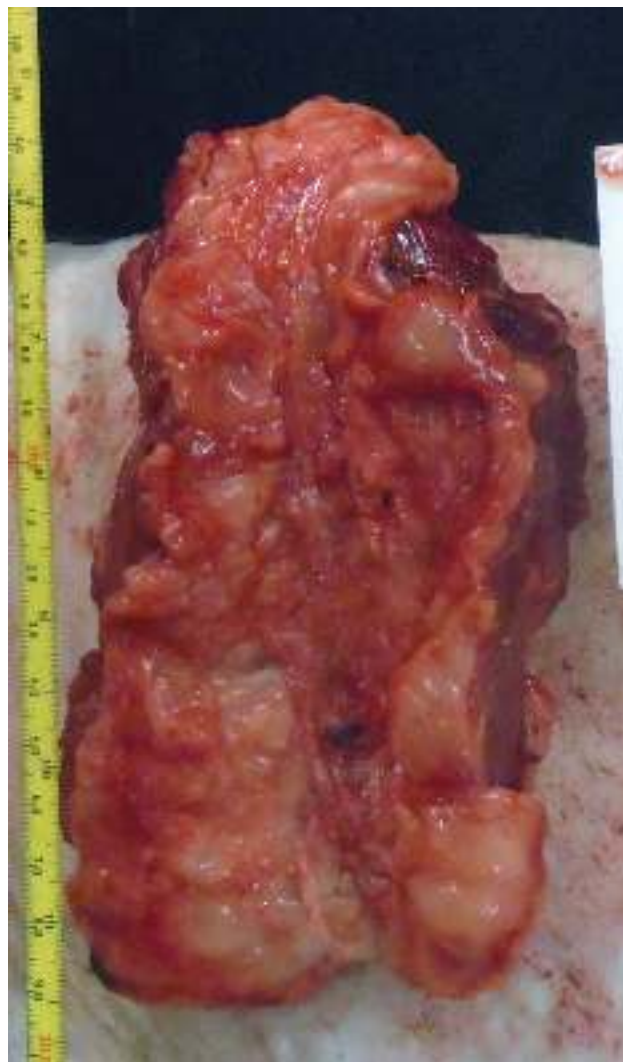

Fig. 5. Peritoneal surface of excised abdominal wall at necropsy. No abdominal defects are noted in this specimen closed with number 1 suturable mesh. A single loop of mesh is seen in the midline, approximately 2/3 of the way between xyphoid and umbilicus.

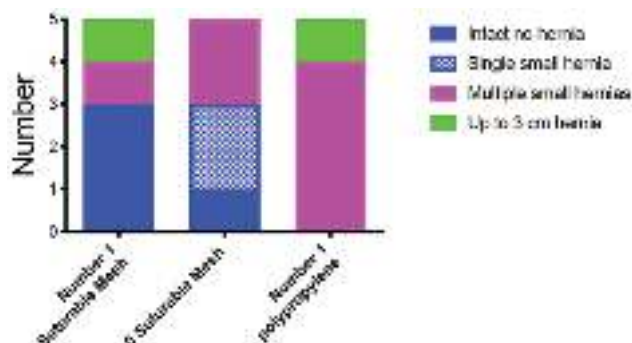


Fig. 6. Hernia outcomes for three groups.

incisions remained well healed with incidental skin lesions found equally in all three groups. Surgical site occurrence was noted in two animals with seromas that resolved spontaneously (one seroma in suturable mesh group, one in polypropylene group). Nine of the 10 suturable mesh

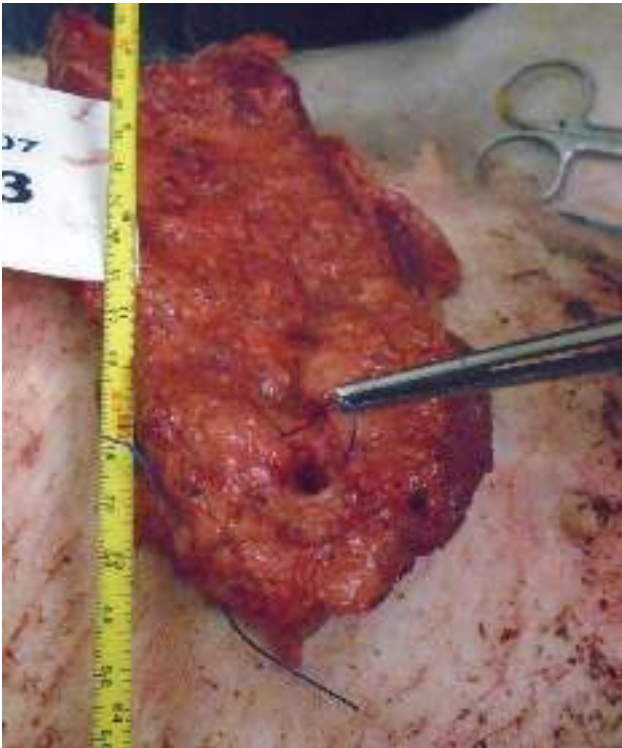


Fig. 7. Image of peritoneal side of abdominal wall showing a loose number 1 polypropylene suture and a 1.0 cm in diameter incisional hernia.

devices were well-incorporated within the tissues and could not be pulled away (Fig. 9), whereas four of the five polypropylene sutures were loose (Fig. 7). Visceral adhesions to the suture line were observed in two pigs closed with 0 suturable mesh and two pigs closed with number 1 polypropylene. Use of the preoperatively defined grading scale for adhesions showed two number 1 polypropylene monofilament suture animals to have a scores of 1 for severity and degree, and scores of 1 and 2 for extent. The 0 suturable mesh animals had similar adhesion scores in two animals as the number 1 polypropylene group. There were no adhesions noted to the closure line with number

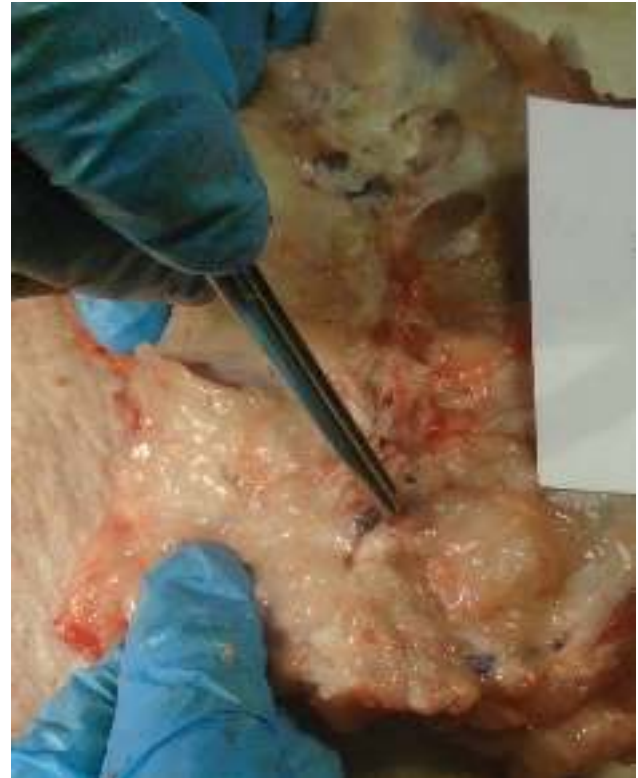


Fig. 9. Surgeon pulling on a number 1 suturable mesh that is visible on the peritoneal surface of an abdominal wall at necropsy. What is demonstrated is incorporation of the suturable mesh—the opposite of the “loose sutures” seen with monofilament suture.

1 suturable mesh. There were 21 adverse events (two soft-tissue swellings thought to be seromas that resolved, lameness, skin lesions found to be unremarkable by pathology, and one febrile illness with weight loss), and none were thought related to the implant used for closure.

DISCUSSION

The attributes of sutures and their intrinsic failure patterns have been accepted by the surgical community and have not been questioned since the dawn of modern surgery. We believe, as others do others, that suture pull-through due to the action of an implant under tension on the encircled tissue is the primary cause of failed tissue approximations.^{10,11} Suturable mesh is a tissue approximation device that increases the implant surface area contacting the tissues in comparison to a standard suture. With fibrovascular ingrowth, the individual filaments act as a scar scaffold and become microencapsulated over time. Although the surface area of number 1 suturable mesh is over 500% times greater than the surface area of a number 1 monofilament, the total volume of foreign material is only 35% increased. The total volumes must be similar for both implant types to fit into the end of a standard swaged surgical needle.

Number 1 suturable mesh had three of the five closures with completely intact abdominal walls. One of the five closures with 0 suturable mesh was completely intact. None of the polypropylene closures were perfectly closed.

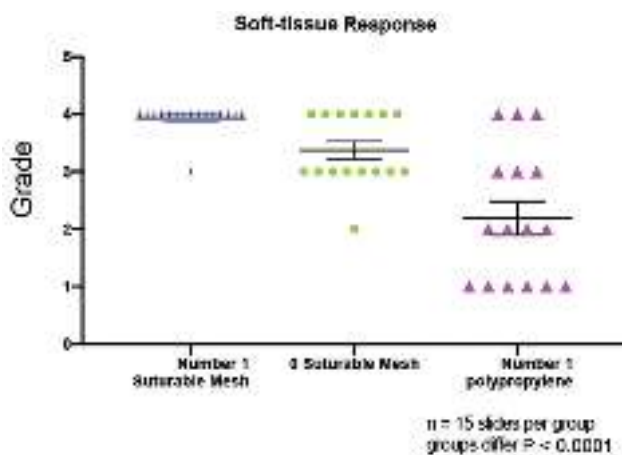


Fig. 8. Grade of soft-tissue response for the three implants.

A “small-bites” closure technique may have demonstrated improved hernia outcomes. A “large-bites” closure with 1-cm bites and 1-cm travels was performed to put more stress at the suture/tissue interface and perhaps demonstrate differences between the closure devices. The data point to the suturable mesh having superior outcomes for tissue approximation, but also to be noted that this is a highly stressed model with human-sized pigs that grew to over 300 lbs during the study. No maneuvers were taken to limit the animals’ activity after the procedure to lessen the stress on the repairs. The animals are quadruped ambulators with all of their torso weight on their closures. Although only four of 15 closures were completely intact, it is almost surprising that any of these closures survived until necropsy.

Polypropylene was chosen for the implant material based on its nonreactivity to tissues and its long-standing use in surgery. The foreign body reaction and microencapsulation will produce a permanent support to the suture line. This may be important in abdominal wall surgery, where scar without a permanent implant is only 70% as strong as uninjured tissue.¹² Some surgeons may prefer an absorbable product, and this is in development.

The optically measured size of the soft-tissue response was larger with number 1 suturable mesh than for number 1 polypropylene, though the intensity or quality of the tissue response measured using the ISO 10993-6 Annex E grading scale was judged to be equivalent. The latter makes sense, as both implants are manufactured from polypropylene. This data illustrate the mechanism by which small filament meshes provide support to tissues and to newly opposed suture lines.

Four of the five polypropylene monofilament running sutures were loose at necropsy. Loose permanent sutures are the hallmark of pull-through.¹³ As the animals doubled in size during the study, the only means for sutures to become loose is for the tissue encircled within the suture loop to become narrower in diameter. The one suturable mesh recorded as being loose was at the site of a small hernia defect. For this animal, the remainder of the laparotomy closure line demonstrated a well-incorporated implant.

The histological outcomes demonstrate a controlled inflammatory tissue reaction. Suturable mesh was graded to be a “nonirritant” to the tissues in comparison to monofilament polypropylene, but there is a multiplication of this “normal” tissue response due to the multiple filaments of the suturable mesh implant. The soft-tissue response may elucidate the mechanism by which meshes reduce pull-through in current methods of abdominal wall tissue approximation.¹⁴

Adhesions were least in the number 1 suturable mesh group and greatest in the other two groups. Although each group had essentially no foreign material exposed to the viscera, perhaps it is the inflammation of slow tearing from suture pull-through that causes the bowel to adhere to a newly closed suture line. The animal group with the best “hold” and least pull-through (number 1 suturable mesh) therefore also had the least adhesions, but this is only a theory.

Suturable mesh demonstrated an ability to approximate tissues under tension in this realistic porcine laparotomy closure model in human-sized pigs. This preclinical

study is an extension of prior work that showed a suturable mesh porcine laparotomy repair required double the force to fail as compared to polypropylene monofilament suture.⁶ Further studies are underway to better define the utility of suturable mesh for internal closures.

Gregory A. Dumanian, MD

Division of Plastic Surgery
Northwestern Feinberg School of Medicine
675 N. St. Clair, Suite 19-250
Chicago, IL 60610
E-mail: gdumania@nm.org

ACKNOWLEDGMENT

The author would like to thank investigator Raelene Petracek at the Prairie Swine Centre for her conscientious and diligent work to perform this study and Zari Dumanian for operating room assistance.

REFERENCES

- Jairam AP, Timmermans L, Eker HH, et al; PRIMA Trialist Group. Prevention of incisional hernia with prophylactic onlay and sublay mesh reinforcement versus primary suture only in midline laparotomies (PRIMA): 2-year follow-up of a multicentre, double-blind, randomised controlled trial. *Lancet*. 2017;390:567–576.
- Deerenberg EB, Harlaar JJ, Steyerberg EW, et al. Small bites versus large bites for closure of abdominal midline incisions (STITCH): a double-blind, multicentre, randomised controlled trial. *Lancet*. 2015;386:1254–1260.
- Luijendijk RW, Hop WC, van den Tol MP, et al. A comparison of suture repair with mesh repair for incisional hernia. *N Engl J Med*. 2000;343:392–398.
- Burger JW, Luijendijk RW, Hop WC, et al. Long-term follow-up of a randomized controlled trial of suture versus mesh repair of incisional hernia. *Ann Surg*. 2004;240:578–583.
- Souza JM, Dumanian ZP, Gurjula AN, et al. In vivo evaluation of a novel mesh suture design for abdominal wall closure. *Plast Reconstr Surg*. 2015;135:322e–330e.
- Dumanian GA, Tulaimat A, Dumanian ZP. Experimental study of the characteristics of a novel mesh suture. *Br J Surg*. 2015;102:1285–1292.
- Scheiber CJ, Kurapaty SS, Goldman SM, et al. Suturable mesh better resists early laparotomy failure in a cyclic ball-burst model. *Hernia*. 2020;24:559–565.
- Ibrahim MM, Green JL, Everitt J, et al. Soft tissue anchoring performance, biomechanical properties, and tissue reaction of a new hernia mesh engineered to address hernia occurrence and recurrence. *J Med Device*. 2019;13:0450021–0450029.
- Melman L, Jenkins ED, Hamilton NA, et al. Histologic and biomechanical evaluation of a novel macroporous polytetrafluoroethylene knit mesh compared to lightweight and heavyweight polypropylene mesh in a porcine model of ventral incisional hernia repair. *Hernia*. 2011;15:423–431.
- Ellis H, Gajraj H, George CD. Incisional hernias: when do they occur? *Br J Surg*. 1983;70:290–291.
- Höer J, Fischer L, Schachtrupp A. Laparotomy closure and incisional hernia prevention - what are the surgical requirements?. *Zentralbl Chir*. 2011;136:42–49.
- Hollinsky C, Sandberg S. Measurement of the tensile strength of the ventral abdominal wall in comparison with scar tissue. *Clin Biomech (Bristol, Avon)*. 2007;22:88–92.
- Dumanian GA, Moradian S. Fascial closure: new surgery paradigms. *Adv Surg*. 2020;54:215–229.
- Dumanian GA, Lanier ST, Souza JM, et al. Mesh sutured repairs of contaminated incisional hernias. *Am J Surg*. 2018;216:267–273.